

Physical therapy in the treatment of body aesthetics dysfunctions - literature review.

Fisioterapia no tratamento das disfunções estéticas corporais – revisão de literatura.

Jane Guiname Mota Silva⁽¹⁾, Eduardo Filoni⁽²⁾, Fátima Faní Fitz⁽³⁾.

Universidade de Mogi das Cruzes (UMC), São Paulo (SP), Brazil.

Abstract

Introduction: The aesthetic disorders, such as skin laxity, localized fat and cellulite, are common complaints among the population in general. The physiotherapy provides techniques for treatment of these dysfunctions noninvasively.

Objective: To review the physical therapy techniques used to treat the body dysfunction aesthetic through a literature review. **Method:** It was performed a literature review of studies published between September/1997 and October/2013, in Portuguese or English, in the Scielo, PEDro, Pubmed, Lilacs e Medline database. **Results:** A total of 1.165 articles were found. Of these, 37 were potentially eligible after reading the title and summary, and a total of 11 studies were included. The studies addressed some techniques like radiofrequency, combination of bipolar radiofrequency, infrared, vacuum and mechanical massage (Velashape), ultrasound of high intensity focused, cellulite cream, mechanical massage, lymphatic drainage and tissue manipulation, ultrasound of low intensity, and cryolipolysis. **Conclusion:** We conclude that the physical therapy techniques are effective, safe and well tolerated by patients in the treatment of localized fat. They help to sculpt the body and to reduce cellulite. However, it is necessary to perform randomized controlled trials, with larger sample size, since the majority of the included studies are prospective and retrospective clinical trials.

Keywords: Localized Fat. Skin Laxity. Body Contouring. Cellulite. Physical Therapy.

Resumo

Introdução: As disfunções estéticas, como a frouxidão tecidual, a gordura localizada e o Fibro Edema Gelóide (FEG), são queixas comuns entre a população de forma geral. A fisioterapia disponibiliza técnicas para tratamento destas disfunções de maneira não invasiva. **Objetivo:** Revisar as técnicas fisioterapêuticas utilizadas para o tratamento das disfunções estéticas corporais por meio de uma revisão de literatura. **Método:** Foi realizada uma revisão bibliográfica de estudos publicados entre setembro/1997 e outubro/2013, em português ou inglês, nas bases de dados Scielo, PEDro, Pubmed, Lilacs e Medline. **Resultados:** Um total de 1.165 artigos foram encontrados. Destes, 37 foram potencialmente elegíveis após a leitura do título e resumo, e um total de 11 estudos foram incluídos. Os estudos abordavam as técnicas de radiofrequência, a combinação de radiofrequência bipolar, infravermelho, vácuo e massagem mecânica (Velashape), ultrassom de alta intensidade focalizado, creme anticelulite, massagem mecânica, drenagem linfática e manipulação de tecidos, ultrassom de baixa intensidade e criolipólise. **Conclusão:** Conclui-se que as técnicas fisioterapêuticas abordadas nos estudos incluídos são eficazes, seguras e bem toleradas pelos pacientes para o tratamento da gordura localizada, auxiliando a esculpir o corpo, além de ajudar na redução do FEG. Entretanto, existe a necessidade da realização de ensaios clínicos randomizados e controlados e com tamanho amostral maior, visto que a maioria dos estudos incluídos são ensaios clínicos prospectivos não controlados e estudos retrospectivos.

Palavras-chave: Gordura Localizada. Flacidez de Pele. Contorno Corporal. Celulite. Fisioterapia.

Received: 6 June 2014. Accepted: 8 September 2014. Published: 16 September 2014.

1. Physical Therapy Student at Universidade de Mogi das Cruzes (UMC), São Paulo (SP), Brazil.
2. Coordinator and professor of Physical Therapy School, Universidade de Mogi das Cruzes (UMC), São Paulo (SP), Brazil.
3. Professor of Physical Therapy School, Universidade de Mogi das Cruzes (UMC), São Paulo (SP), Brazil.

Corresponding Author

Fátima Faní Fitz - Universidade de Mogi das Cruzes, Centro de Ciências Biomédicas - Avenida Imperatriz Leopoldina, 550 - Vila Leopoldina - Zip Code: 05305-000 - São Paulo, SP - Brazil - Phone: (11) 3648-5050 - E-mail: fatima.fitz@umc.br

INTRODUCTION

The tissue laxity, the subcutaneous fat deposit located on the body and "cellulite" are the most common complaints among patients treated by Dermato-Functional physiotherapy. Among the causes of these disorders are the chronological aging, photo aging, changes in body size experienced during pregnancy and weight loss.⁽¹⁾

The "cellulite" has a prevalence between 85% and 98% in all ethnic groups. Among the risk factors that contribute to its emergence are excess body fat, hormonal factors, inadequate diets, genetic predisposition, smoking, postural and orthopedic disorders, inactivity and also external compression of body tissues caused by wearing tight clothes.⁽²⁾ Although the main complaint is related to aesthetics, sagging skin, excess body fat and "cellulite" cause functional and emotional problems and may lead to decreased self-esteem and creating problems in interpersonal relationships.^(3,4) Thus, these disorders are considered a health problem, by presenting major impact on quality of life of women.⁽⁵⁾

Dermato-Functional physiotherapy has worked to correct these dysfunctions, using resources that operate noninvasively, improving the quality of life of these patients.⁽⁶⁾ Given the great demand for non-invasive procedures, as well as the motivation of researchers to develop new techniques to replace surgical treatments to improve body contour,^(7,8) this study aims to review the physical therapy techniques used to treat bodily dysfunctions aesthetic through a literature review.

METHODS

The work refers to a literature review of published scientific articles in Portuguese and English, published between September to October 1997/2013. The Medline, Pubmed, PEDro, SciELO and LILACS databases were used to conduct the research. The following descriptors according to the Medical Subject Headings (MESH) were used: skin laxity, fat, physical therapy modalities, aerobic exercise, galvanic current, exercise, muscle stretching, exercise, pilates, radiofrequency and ultrasound. Articles reporting the role of physiotherapy in the treatment of bodily aesthetic disorders were included. Considered aesthetic bodily dysfunctions localized fat, cellulite and laxity skin. No studies of narrative and editorial review were included, because they did not fit the criteria proposed by the study.

RESULTS

A total of 1,165 studies were found after removing duplicates. Of these, 37 were considered potentially eligible after reading the title and abstract. A total of 11 studies were included after reading in full. Details of inclusion and exclusion studies are shown in Figure 1. The details of the studies included were tabulated and are shown in Table 1.

DISCUSSION

Physiotherapy Dermato-Functional acts in the prevention and recovery of the integumentary system, treating metabolic, circulatory and endocrine dermatological disorders, aiming body aesthetic and functional recovery. Radiofrequency techniques were used in this study, the combination of bipolar radiofrequency, infrared, vacuum and mechanical massage (Velashape), high-intensity focused ultrasound, cream called "cellulite", mechanical massage, lymphatic drainage and tissue manipulation, ultrasound low intensity and cryolipolysis. The following will be presented and discussed each of the techniques discussed in the included studies.

Radiofrequency and aesthetic body dysfunctions

The radiofrequency has been applied to reduce "cellulite". Induction diathermy has a favorable effect on microcirculation and tissue oxygenation, and can also lead to the renewal of collagen, such as stimulation of fibroblasts increases the production of collagen and elastin (the latter responsible for improving elasticity and firmness skin). As reported in the literature, the use of radio frequency leads to a noticeable improvement in the appearance of skin affected by "cellulite" areas.⁽⁴⁵⁻⁴⁷⁾

Proper technique can be low or high frequency monopolar, bipolar or tripolar application. In the application of monopolar device, an electrode is located in the target area and the other return electrode is placed at a certain distance, so that the electric current passes through the tissue between the electrodes. Bipolar implementation, both electrodes are embedded in a single tool.⁽⁴⁸⁾ Can be also used to tripolar application, which is based on three or more electrodes. In this, as in others,

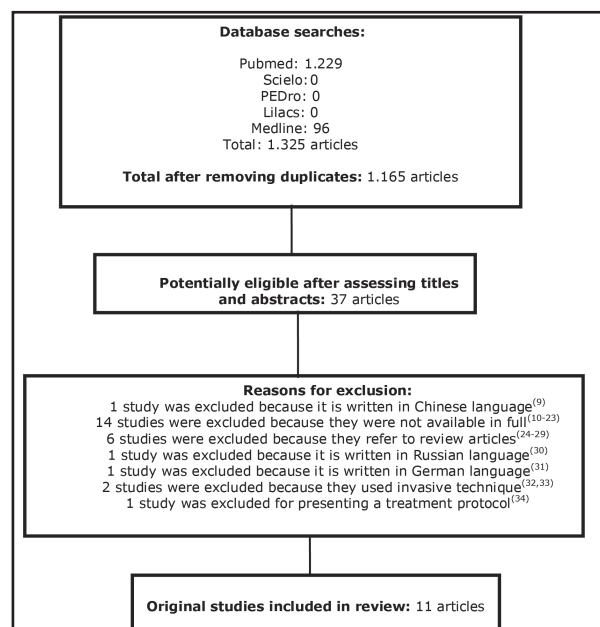


Figure 1. Flowchart of the inclusion and exclusion criteria.

Table 1. Details of the included studies.

Author/ Year	Characteristics of participants, sample size (N), duration of symptoms	Study Design and Interventions	Measures of Outcome, Results and Conclusion.
Dierickx et al, 2013 ⁽³⁵⁾	<p>N= 518 Inclusion Criteria: Different ages, men and women, with a medical history and different type of skin and presence of localized fat. Exclusion Criteria = Not reported</p>	<p>Type of Study= Multicenter retrospective study. Protocol= cryolipolysis.</p>	<p>Measures of Outcome = Evaluate the safety and tolerability of cryolipolysis. Effectiveness of treatment according to patient satisfaction (scale of 4 points -very satisfied, satisfied, neutral, dissatisfied). Results = No significant side effects or adverse events were reported. The procedure was well tolerated, with 89% of respondents reporting positive perception of treatment. 73% of patients were satisfied. In assessing body fat observed a 23% reduction in the thickness of the fat layer. Conclusion= The cryolipolysis is a safe, well-tolerated and effective treatment is a good and non-surgical method for reducing subcutaneous fat.</p>
Ferraro et al, 2012 ⁽⁴⁾	<p>Age = Between 21 and 62 years. N= 50 Inclusion Criteria= 37 women and 13 men with the presence of localized fat and cellulite. Exclusion Criteria = Men and women with osteoporosis, phlebitis, thrombophlebitis, patients with metal fragments, joint prostheses and intrauterine, pregnant women, patients with reduced nervous sensibility, neurological disorders, patients affected by arteriopathies, significant inflammation or neoplastic diseases.</p>	<p>Type of study= Prospective clinical study. Protocol = We used simultaneous two transducers: a probe for freezing fatty tissue (cryolipolysis) and low-intensity ultrasound to cellulite. The cryolipolysis was carried out for 30 minutes with sliding area with slow movements and a temperature range between 0 and -5 °. The low intensity ultrasound has been used with a conductive gel for 10 to 15 minutes. For edematous cellulite, the probe was used to freeze for 5 minutes and then used the shock probe for 5 minutes. The cryolipolysis and low-intensity ultrasound was repeated four times (20 minutes each side) for localized fat, and for fibrous cellulitis were used 10 minutes of low intensity ultrasound and 10 minutes of cryolipolysis. The duration of treatment was defined as the size of the area being treated, minimum of 20 minutes and a maximum of 60 minutes. 1 session every 15 days for 8 consecutive weeks.</p>	<p>Measure of outcomes = Patients were examined by two surgeons not involved in the treatment. Weight and height of each individual was recorded. The follow-up period was 12 months, and the method of evaluation of post-treatment was standardized. Subjective assessment of skin density and volumetric fat reduction was made. The assessment of patients was obtained through a questionnaire with a scale 0-5 pertaining to comfort and satisfaction. Results = Reduction in the thickness of body fat after treatment was 3.02 cm and the body circumference was 4.45 cm. The weight remained unchanged during the treatment, and no adverse effects were observed and a reduction in fat thickness was accompanied by a significant improvement in microcirculation and cellulite. Conclusion= The Results shows that the action of cryolipolysis and low-intensity ultrasound is safe, well-tolerated and effective ways as non-invasive procedure for body contouring treatment.</p>
Mlosek et al, 2012 ⁽³⁶⁾	<p>Age= 24-58 years. N= 45 Inclusion Criteria= Women with cellulite stage I to III. Exclusion Criteria= Not reported.</p>	<p>Type of study= Prospective clinical study. Protocol = Treatment group: 28 women treated with radiofrequency. The treatment began with the lower energy dose recommended by the manufacturer (110 J/cm²) which was increased by about 10-20 J/cm². Placebo group: 17 women who underwent treatment without increasing the transmitter. Placebo group: 17 women who underwent treatment without increase increasing the transmitter.</p>	<p>Measures of outcomes = Measurements were performed in a traditional way, by palpation performed before and 4 weeks after completion of therapy. The stage of cellulite was evaluated according to the scale of Numberger-Müller, and thigh circumference and body mass index was calculated to be measured. Results = The cellulite was reduced in 89.2% of women who underwent treatment with radiofrequency. After treatment, the following observations were made: there was a reduction in the thickness of the dermis and subcutaneous tissue, increased echogenicity in reflection on the increased number of collagen, decreased subcutaneous tissue growing in bands fibers in the dermis, and the reduction edema. In the placebo group, there were no statistically significant changes. Conclusion = The radio frequency enables a reduction in cellulite.</p>

Mlosek et al, 2011 ⁽³⁷⁾

Age= 22-61 years

N= 61

Inclusion Criteria = Women diagnosed with cellulitis based on palpation exam.

Exclusion Criteria = Not reported.

Type of study= Prospective controlled clinical study.

Protocol = Group treatment: cellulite cream used for 30 days. The cream was used in the cellulite affected area by 2X/day. Control group: They ingested placebo medication in tablet form for 30 days.

Measures of outcomes = In classic ultrasonic examinations were evaluated: the thickness of the hypodermic layer and the total thickness of the dermis and subcutaneous tissue. In ultrasound imaging at high frequency was evaluated: the thickness of the epidermis, the dermis thickness, echogenicity, and the presence or absence of edema of the dermis.

Results = A statistically significant difference was observed in the thickness of the subcutaneous tissue in echogenicity in the surface area and length of the subcutaneous tissue as well as the presence of edema in the treatment group. Discussed the changes were not observed in the placebo group.

Conclusion = Ultrasound classic and high frequency are useful for monitoring "anti-cellulite" therapy methods.

Jewell et al, 2011 ⁽³⁸⁾

Age= 18-65 years

N= 180

Inclusion Criteria = Men and women with BMI ≤ 30 kg/m² and thickness of subcutaneous adipose tissue in the abdomen and flanks ≥ 2.5 cm.

Exclusion Criteria= Coagulation disorders or use of medications, dietary supplements limiting coagulation or platelet aggregation, diabetes or cardiovascular disease; any previous cosmetic procedure, surgical scar or laparoscopy in the treatment area; skin disease, abnormalities of skin or soft tissues of the abdominal wall, sensory loss, dysesthesia, or metal implants for weight loss; Surgical procedures for weight reduction, use of current treatment with steroids or immunosuppressive chronically; implantable fixture, history of cancer; use of illicit drugs or alcohol (ie, four or more drinks per day and pregnant and lactating women also patients who did not agree to change your diet, participate in any program of weight loss were excluded; using any substance for promoting weight loss, or to undergo any cosmetic procedure (including surgery) of the trunk, back, or abdomen.

Type of study= Multicenter, randomized double-blind controlled.

Protocol = Subjects were randomized into three groups to receive High Intensity Focused Ultrasound (HIFU) with different doses in regions of the anterior abdomen and flanks. The groups were: 47 J/cm² (141 J/cm² total); 59 J/cm² (177 J/cm² total); or 0 J/cm² (control group).

Measures of outcomes = The first method was effective shift in height of the circumference of the iliac at 12 weeks after initiation of treatment.

The second method of efficacy included change in waist circumference into 4 and 8 weeks. At 12 weeks the patients completed a satisfaction survey which gave a score 1-5 to questions such as: perception of improvement in abdominal structure, intention to purchase additional treatment, and overall satisfaction with the results.

Within 7 days following treatment, patients rated the level of discomfort and pain that felt like medications being taken.

Researchers assessed the degree of aesthetic improvement in 4th, 8th and 12th week based on photos.

Side effects and blood samples were analyzed before and after treatment.

Results = In assessing the extent of the circumference at the level of the iliac crest, there was significant improvement for the 59 J/cm² group compared with the control group, however, this was not observed in the result group 47 J/cm². In the investigation of subjective measures of overall aesthetic improvement and patient satisfaction were favorable in the treatment groups compared to control. Adverse events, such as discomfort, bruising and swelling were rated mild to moderate.

Conclusion = Treatment with high-intensity focused ultrasound reduces waist circumference is well tolerated to sculpt the body non-invasively.

Fatemi et al, 2010 ⁽³⁹⁾

Age= 22-69 years

N= 85

Inclusion Criteria = healthy adults who expressed a desire to undergo body sculpting with High Intensity Focused Ultrasound (HIFU), have at least 1 cm of adipose tissue beyond the focal depth planned to be used, and no contra indications exist for the use of HIFU.

Exclusion Criteria= Body mass index less than 30 kg/m², pregnancy, implanted electrical devices, clotting or current anticoagulant therapy, cancer, hernia, sensory loss in the area being treated, or suspected systemic or chronic disease.

Type of study= Clinical retrospective study.

Protocol = One session of High Intensity Focused Ultrasound (HIFU) lasting 60-90 minutes.

Measures of outcomes = Evaluation of waist circumference was performed before treatment and after 8 to 12 weeks. During a post-treatment with 4 months of follow-up visits. Fifty patients were randomly selected for a brief survey to assess their overall satisfaction with the procedure and conduct of their aims to reduce waist circumference.

Results = Waist circumference decreased by an average of 4.6 cm after 3 months. Of the 85 treated patients, 10 (11.8%) reported adverse events, including prolonged sensitivity (n=3), ecchymoses (n=3), pits (n=2), or swelling and pain (n=1).

Conclusion = The authors conclude from their experience that HIFU is a safe and effective means of treatment to sculpt the body non-invasively.

Trelles et al, 2010⁽⁴⁰⁾

Age= 24-47 years
N= 30
Inclusion Criteria= Women with photo skin types II to V, with grades (grade 3) similar cellulite on the buttocks.
Exclusion Criteria = Previous treatment for cellulite.

Type of study = Prospective study.

Protocol = Patients received 1 session of bipolar pulsed radiofrequency. Treatment sessions were conducted with a 22cm transducer. Gel to improve contact between the transducer and the skin was used and was placed in noticeable pressure transducer at the time of treatment, while, if the traced figure of eight movement with the skin tissue in an upward direction. Termination of treatment was prolonged when a temperature of the skin surface of about 42°C was observed, or when pain or burning sensation was felt, or presence of intense erythema. The duration of the treatment session was 45 minutes. At the end of the session was applied Aloe Vera gel serving as a moisturizer.

Measures of outcome = Biopsy of the subcutaneous layer of the cellulite area (buttocks) immediately after the first treatment session performed.

Results = Following treatment with radiofrequency epidermis had a thin layer of keratin which would have been related to the frequent passage of the tool. In all histological samples collected after treatment of the keratin layer was thinner than in samples taken before treatment, but the keratin layer was thinner not comparable to that produced by a chemical peeling agent. The dermis showed collagen fibers realigned and slightly apart, with edema and lymphocytic infiltrate around the dilated vessels. In all samples, adipocytes had lost their round shape and rectangular polyhedral presenting. Furthermore, some adipocytes appeared necrotic and without any fat content.

Conclusion = The radiofrequency treatment produces a decrease in cellulite in lipid content as well as changes in adipocyte cell membrane, leading to disruption and cell death and lipid content of extruded out of the cell. More studies are needed to characterize the nature of the material showed that extracellular lipid with oil red stain in biopsies.

Bayrakci et al, 2010⁽⁴¹⁾

Age= Over than 30 years.
N= 60
Inclusion Criteria= Women with degree of cellulite ≥ 2 according to the scale of Nürnbergger Score.
Exclusion Criteria = Heart disease, liver disease, hypothyroidism, pregnancy, hematologic diseases, therapy with aminophylline and theophylline, varicose veins, diet or recent weight loss, liposuction or other surgery for the thighs and buttocks.

Type of study= Prospective

Protocol = First group (n=20) compared mechanical massage. Three sessions/week for 5 weeks. Second group (n=20) using the technique of manual lymph drainage. Four sessions/week for 5 weeks. Third group (n=20) using the technique of connective tissue manipulation. Four sessions/week for 5 weeks.

Measure of outcomes = The participants were evaluated using standardized photographs, analysis of body composition, body weight, body mass index, % fat, fat mass, fat free mass, total body water, measurement of thigh circumference, waist-hip ratio, measurements of fat thickness of the abdomen, flanks and thigh regions with folded skin.

Result = All groups had decreased subcutaneous fat after treatment ($p < 0.05$). The thigh circumference decreased by an average of 0.5 cm in all groups. The thickness of thigh fat decreased 1.66 mm in Group 1; 2.21 mm in Group 2 and 3.03 in Group 3 mm. Region of the abdomen and flanks decreased 2.4 and 2.58 mm of fat thickness in Group 1, 1.78 and 2 mm in Group 2 and 1.23 and 0.64 mm in Group 3, respectively. The average difference in waist-hip ratio was 0.1 cm in all groups.

Conclusion= All treatment techniques are effective to reduce fat located in patients with cellulite.

Brightman et al, 2009⁽⁴²⁾

Age= 28-70 years.
N= 29
Inclusion Criteria = Age ≥ 21 years and at least nine months postpartum, significant sagging skin and subcutaneous fat deposits, as determined by the investigator, postmenopausal women, tubal ligation or filling out a form of birth control.
Exclusion Criteria = Known photosensitive disease, use of substances that cause photo sensitivity, keloids, isotretinoin within 6 months of treatment, use of nonsteroidal anti-inflammatory drugs two weeks before or two weeks after treatment, pregnancy or breastfeeding, history of cancer in the area treated, treatment with a laser or other device areas of study within 6 months of study treatment or in the treatment zones intended for treatment within 9 months during the study or treatment, having undergone any surgery in the treated areas within 9 months during the study or treatment, or suffering from hormonal imbalance that may affect the weight or cellulite.

Type of study= Non randomized clinical trial.

Protocol = Treatment of the upper extremities: 19 patients underwent five weekly sessions with Velashape. Treatment of the abdomen and flanks: 10 subjects underwent 4 weekly sessions with Velashape. *Velashape* - combinação de radiação infravermelho (*Infrared*) (20W/700-1,500 nm), com radiofrequência bipolar (50W), vácuo (200mbar - pressão negativa 750 mmHg) e massagem mecânica.

Measures of outcome = Measured of circumference, photographs and body weight measurements were performed before treatment and at 1 and 3 months follow-up. Assessment of treatment satisfaction (not satisfied, somewhat satisfied, satisfied, very satisfied, very satisfied) to each follow-up visits.

Result = Change in arm circumference at the fifth session of treatment was statistically significant with an average loss of 0.62 cm. At 1 and 3 months follow-up, the average loss was 0.71 and 0.59 cm, respectively. Reduction in abdominal circumference in the third session of treatment was statistically significant with a reduction of 1.25 cm. At 1 and 3 months follow-up, the average loss was 1.43 and 1.82 cm, respectively.

Conclusion = This study demonstrates statistically significant, sustainable circumference reduction and improvement in the appearance of the arms and abdomen treatment with Velashape.

Christ et al, 2008⁽⁴³⁾**Age**= 21-63 years.**N**= 59**Inclusion Criteria** = Age > 20 years, stage 2 or 3 of cellulite according to Nürnberger Score scale, and ability to read and understand the informed consent form.**Exclusion Criteria** = gravidez e amamentação, flebite ou trombose venosa profunda em MMII, inflamação na região da terapia, lipoaspiração ou endermologia na região da terapia menos de 6 meses antes do estudo, graves problemas cardiovasculares, marcapasso, áreas de dor difusa, e o uso de antagonistas da vitamina K.**Type of study** = Controlled trial**Protocol** = Group A: 15 patients underwent treatment of plane acoustic waves with six sessions of therapy for 3 weeks.

Group B: 44 patients underwent treatment of plane acoustic waves with eight therapy sessions over 4 weeks.

The treatment was performed with a portable device plan. This includes a source of acoustic wave and connector membranes that are placed on the skin equipment. Applies ultrasound gel on the skin before, to avoid energy losses due to air layer between the connector membranes and skin.

Measures of outcome = The changes in the connective tissue were evaluated using the Super System DermaScan-C. Measurements of skin elasticity were performed using the system Dermalab. Photos of the treated areas were taken at each therapy and at follow-up.**Result** = Skin elasticity improved gradually during the course of therapy in 73% of patients and increased at the end of therapy. At 3 and 6 months follow-up, skin elasticity had improved by up to 95%. The side effects include pain for three patients during therapy and slight reddening of the skin.**Conclusion** = This study confirmed the effects of acoustic waves in biological tissue therapy, including pacing, improvement of microcirculation and cell permeability. Ultrasonography showed increased density and firmness of the collagen / elastic fibers in the dermis and subcutaneous tissue network. The treatment was most effective in older patients with a long history of cellulite.Moreno-Moraga et al, 2007⁽⁴⁴⁾**Age**= Not reported**N**= 30**Inclusion Criteria** = Fat located at least 2 cm in thickness measured with a compass, and physical examinations and blood.**Exclusion Criteria**= Patients with active malignant disease other terminal or severe liver disease, or severe hyperlipidemia, large tattoos or scars in the area of disease treatment.**Type of study**= Prospective**Protocol** = 8 men and 22 women underwent three sessions of High Intensity Focused Ultrasound (HIFU), with 1-month interval, and were followed for one month after the last session. The treated areas are the abdomen, inner and outer thighs, flanks, inner knees, and in men with pseudo-gynecomastia.**Measure of outcome** = Efficacy was assessed by changes in thickness of the fat measured by ultrasound and by measuring the circumference. Weight change was monitored for evaluating if the reduction in thickness of fat or circumference was dependent or independent of weight loss. Photographs were taken before and after each treatment session.**Result** = All patients showed a significant reduction in the thickness of subcutaneous fat in the treated area. The weight remained unchanged during treatment and follow-up. No adverse effects were observed.**Conclusion** = This study demonstrates the efficacy and safety of HIFU is a non-invasive transdermal method to reduce the fat deposit in the body.

power is generated when current passes between the electrodes.⁽⁴⁹⁾

In this review, three studies addressed the radiofrequency. Mlosek *et al.*⁽³⁶⁾ used technique in radiofrequency pole eight sessions of treatment of "cellulite." The authors observed a decrease in the thickness of the dermis and subcutaneous tissue, increase in the number of collagen fibers, reduction in subcutaneous tissue growth bands in the dermis, and a reduction of the edema. The technique was effective for reducing cellulite and safe for not expressing side effects.⁽³⁶⁾

In another study, which does not focus on the treatment of "cellulite", but discusses the reaction of adipocytes, the authors analysed the histological findings of biopsies on the localized cellulite on the buttocks. And found that they showed changes in shape, size and content of lipids, as well as cytoplasmic and nuclear morphology. After treatment, there was a decrease in the lipid content in cells, and changes in the membrane of adipocytes, leading to breakage and cell death and lipid content of extruded out of the cell.⁽⁴⁰⁾

Another study used a combination of bipolar radiofrequency, infrared, vacuum and mechanical massage

(Velashape), in the region of the arms, abdomen and flanks, with the goal of treating localized fat and sagging skin postpartum.⁽⁴²⁾ Velashape is the first medical device to receive certification from the Food and drug Administration (the agency that regulates the sale of food and medicine in the United States), considered the best resource for the reduction of fat and circumference layer, acting effectively in reducing "cellulite ". The use of simultaneous movements of suction (negative pressure), infrared, bipolar radiofrequency and mechanical massage promotes increased metabolism of fat cells, decreasing its size and stimulating the production of collagen, thereby improving skin texture. The combination of dual energy allows synergistic effects preheating the target tissue with infrared, mitigating the impedance and thus allowing greater attraction radio frequency.^(48,50) Brightman *et al.*⁽⁴²⁾ have observed that application of Velashape arm promoted a significant change from the fifth treatment session with an average loss of about 0.6 cm. In the abdomen, the significant loss gave up after the third treatment session, with an average loss of 1.2 cm. It is shown, therefore, an effective treatment in reducing circumference and improves the appearance of the abdomen and upper arm.⁽⁴²⁾

High-Intensity Focused Ultrasound and body dysfunctions aesthetic

Ultrasound can be used in medicine as a diagnostic method, when used in imaging or as a therapeutic modality which emits focused ultrasound waves to deliver energy concentrated in a focal volume at a precise depth in the subcutaneous tissue. This system was designed to use the mechanical energy (not heat) to break down fat cells without damaging nearby structures (skin, blood and lymph vessels, muscles and peripheral nerves).⁽⁴⁴⁾ In the treatment of localized adiposity, a stable cavitation occurs and unstable transitional openings performing cell membranes, termed ultra-cavitation, producing the opening of the interstitial liquid triglycerides. The damage occurring to adipocytes results in an inflammatory response, composed primarily of macrophages, neutrophils, and plasma cells attracted to engulf and transport the damaged cells lymphocytes.⁽³⁹⁾

Fatemi *et al.*⁽³⁹⁾ conducted a retrospective study of a series of cases with the use of high intensity focused ultrasound with only one session. A waist circumference of 85 patients was measured before application of ultrasound and three months after treatment. For the authors, this time was necessary because the damaged fat tissue is reabsorbed within eight weeks after the application of high frequency ultrasound. The authors observed a reduction of waist circumference of about 4.6 ± 2.4 cm after about 3 months of treatment with the use of average energy intensity of 147 J/cm^2 . About 70% of the 50 patients selected for assessment of treatment satisfaction showed themselves satisfied with the results. The authors also evaluated the side effects of HIFU and observed that about 11.8% of the patients had any adverse effects. Among the effects are the presence of altered sensitivity, bruising, presence of hard lumps, swelling and pain. Investigations of cholesterol and triglycerides were performed to confirm the safety of the treatment, not observing changes. Therefore, this technique proved to be effective for body sculpting without being invasive.⁽³⁹⁾

Jewell *et al.*⁽³⁸⁾ used high-intensity focused ultrasound in different doses. Patients were randomized into groups using 47 J/cm^2 (141 J/cm^2 overall), 59 J/cm^2 (177 J/cm^2 total) and a control group that received 0 J/cm^2 . Satisfactory in the study groups (47 J/cm^2 and 59 J/cm^2) results were observed after twelve weeks of treatment. Among the observed side effects are edema and hematoma, and few patients reported pain during treatment and no reported severe pain after its completion. However, due technique is considered safe and efficacious in the reduction of localized fat according to the protocol used.⁽³⁸⁾

The writer Moreno-Moraga and his collaborators, in 2007, used the high intensity focused ultrasound in three sessions separated by an interval of one month between

each session. At the end of treatment was observed that the reduction of fat thickness correlated positively with the initial measurement ($r_s=0.88$, $P<0.01$). Also observed average circumference reduction of 3.95 ± 1.99 cm. The change in circumference was significant compared to baseline ($P<0.01$). Another fact was found that there was no significant variation in weight of the patients, showing that reduction of fat thickness and circumference occurred due to treatment and not due to weight loss, confirming its efficacy. Among the adverse events observed in one case the presence of bubbles, however the procedure was considered safe. As in the study by Fatemi *et al.*, Completing examinations of fatty acids were performed and no significant difference was observed. Also, we carried out the ultrasound examination of post-treatment liver to verify the presence of steatosis, which was not observed, suggesting that the high-intensity focused ultrasound is a safe technique with no adverse physiological effects.⁽⁴⁴⁾

"Anti-cellulite" body lotion and body dysfunctions aesthetic

Hydrolysis of body fat is carried out by the enzyme cyclic adenosine monophosphate (cAMP), which is released in the mitochondria adipocyte cell. The accumulation of fat in the cells is related to the insufficient amount of cAMP produced for burning fat. However, the procedures for the treatment of localized fat deposits and "cellulite" is oriented to increase production of this enzyme by the action of mitochondria. Increased blood and lymphatic circulations are generating internal heat, which leads to mitochondria to increase cAMP production. The Cosmetology uses active ingredients with vehicular ways that promote increased blood and lymphatic circulation, and dissociation of fibrosis fat.⁽⁵¹⁾

The use of cosmetics called "anti-cellulite" was addressed in only one study, which aimed to verify how the ultrasound technique can be used to assess the characteristics of the skin after aesthetic treatment of dysfunctions. In this study two groups were evaluated: the first used a cosmetic "anti-cellulite" and the second placebo pills for 30 days. In the treatment group was noted to decrease the thickness of subcutaneous tissue, probably by improving local circulation, which results from the fact that the cream was used in the thighs twice daily. The way of using the cream should lead to mechanical peeling epidermis. The active ingredients used to obtain the results were the protein of Cucurbita pepo (pumpkin), which aims to protect collagen fibers and prevent their degradation; mulberry extract, which is rich in polyphenols that improve the microcirculation and have oxidizing action; the orange extract, which provides flaking of dead epidermal cells and stimulates microcirculation; and a unique amino acid T containing the functional group of L-carnitine which ser-

ves as a guide for the fatty acids through the mitochondrial membrane.⁽³⁷⁾

Mechanical massage and manual lymphatic drainage in body dysfunctions aesthetic

The authors Bayrakci *et al.*⁽⁴¹⁾ used a mechanical massage, manual lymphatic drainage techniques and manipulation of the connective tissue into three distinct groups. The main finding of this study was that the use of different treatment techniques promote a decrease in the thickness of the regions with accumulation of fat, such as the abdomen, flanks and thighs, when assessed by caliper. However, no change was detected in the percentage of total fat and fat mass, obtained with an instrument measuring bioelectrical impedance. In short, the mechanical massage, manual lymphatic drainage and techniques of manipulation of tissue are presented as safe and effective methods for the reduction of localized fat. For the authors of this study, none of these techniques discussed could replace conventional liposuction surgery, although they may be suitable alternatives for those patients who do not wish to undergo surgery.⁽⁴¹⁾

Already Collis *et al.*⁽⁵²⁾ authors conducted a study with three groups. The first was treated with anti-cellulite cream with active ingredient aminophylline which is a phosphodiesterase inhibitor, the enzyme responsible for the breakdown of cyclic adenosine monophosphate. The second to endermology, which is a mechanical massage. The third combined the two methods, namely, "anti-cellulite" cream and endermology. The results found by these authors were poor, which led them to conclude that the few benefits that must be met more by dietary modification, increased water intake and exercise than by the application of techniques endermology and cellulite cream.⁽⁵²⁾

Low intensity ultrasound and cryolipolysis in body dysfunctions aesthetic

The purpose of using low-intensity ultrasound is the stimulation of microcirculation in the subcutaneous tissue to improve the structural and metabolic changes, reducing the visible signs of "cellulite".⁽⁵³⁾ The biological effects are caused by the release of mediators such as a vascular endothelial growth factor,⁽⁵⁴⁾ which significantly increases angiogenesis and local blood circulation.⁽⁵⁵⁾

The cryolipolysis is a technique that has been considered "non-invasive liposuction", whereby the reduction of the fat layer by the selective destruction of fat cells occurs.⁽⁵⁶⁾ This technique involves exposure to cold reduction to obtain a controlled gradually the subcutaneous fat layer without damage to other tissues.⁽⁵⁷⁾ Adipose tissue is placed in contact with the plates frozen using a pressure applicator that thermally destroys fat without damaging the skin. The dead cells are then metabolically eliminated.⁽⁵⁸⁾ The advantages of cryolipolysis

are the reduction of body fat with reduced complications and risks related to invasive plastic surgery procedures.⁽⁵⁹⁾

Three articles were included in this review. Used two low-intensity ultrasound, and one of these combined with cryolipolysis, and the third used the cryolipolysis in isolation.

In the article the authors Ferraro *et al.*⁽⁴⁾ used the combination of low-intensity ultrasound and cryolipolysis. The procedure was intended to reduce the fat cells and effectively make treatment of the EGF through remodeling of the collagen. There was a mean reduction in circumference of fat at the end of treatment to the abdomen 6.86 cm, 5.78 cm for the thighs, 2.75 cm for arms, 5 cm to the gluteal region, and 2.25 cm for the ankles ($p < 0.05$). The final reduction of fat thickness was significant compared with baseline ($z = -5.38$, $p < 0.0001$). The largest reductions in the thighs and abdomen, regions with higher fat percentage were observed, while the ankles showed the smallest reduction.⁽⁴⁾

The treatment, in addition to improving the stability of connective tissue and skin structure and cause a reduction in adipose tissue, also stimulated the metabolic activity in subcutaneous adipose tissue, a factor that optimizes the flow of oxygen and nutrients, significantly increasing lymphatic drainage. One important aspect that distinguishes this treatment liposuction, for example, is the smallest number of discomfort during treatment, which in some cases becomes zero. Moreover, procedures have been relatively rapid, non-invasive without causing pain, or physical limitations after treatment drawbacks. The conclusion is that the treatment has proved to be effective and safe.⁽⁴⁾

Dierickx *et al.*⁽³⁵⁾ aimed to evaluate the safety, tolerability and patient satisfaction with treatment cryolipolysis. The researchers treated 518 patients. There were no reported significant side effects or adverse events. The procedure was well tolerated, with 89% of respondents reporting a positive perception of the duration of treatment and 96% reporting minimal discomfort tolerable. The survey results showed that 73% were satisfied and 82% of patients would recommend the procedure to a friend cryolipolysis. In the measurement, a reduction of 23% in the thickness of the fat layer in 3 months after treatment was observed. In regions of the abdomen, back and flanks treatment was more effective, noting that in 86% of subjects, there was improvement in the evaluation conducted by the researchers. According to the authors, with a suitable selection of patients cryolipolysis becomes a well-tolerated and effective for the reduction of subcutaneous fat safe method of treatment.⁽³⁵⁾

The authors Christ *et al.*⁽⁴³⁾ used ultrasound with intensity and low pulses, in order to stimulate the metabolic activity in subcutaneous adipose tissue in order

to evaluate the effectiveness of this technique in increasing the strength of the connective tissue and improving the structure and skin texture. There was an increase in cell permeability in the short term, which stimulated the exchange of substances of fat cells and the activation of enzymes that break down fat. The protective and therapeutic effects of acoustic waves are complex and include stimulation of lipolysis, the release of toxic aldehyde products of lipid oxidation, reduction of oxidative stress, reinforcement of antioxidants, a better synthesis of collagen and measurable and visible improvement skin condition. This improves the skin condition was clearly observed by the final evaluation. In Group A (six sessions held over three weeks), the elasticity increased from 45% to 75% in three months; and Group B (conducted 8 sessions over 4 weeks) increased from 73% to 95% in the third month and 105% at six months, indicating that improvement in skin elasticity in the long term can be observed. The authors also state that

the improvement in skin properties, obtained with the use of chemical products (creams or lotions), usually between 12% and 25%, reaching more than 30% in individual cases. This study confirmed the effects of acoustic waves in biological tissue therapy, including stimulation of microcirculation, improvement of cell permeability. The ultrasound examination showed increased density and firmness of the collagen/elastic fibers in the dermis and subcutaneous tissue network. ⁽⁴³⁾

CONCLUSION

We conclude with this review that physiotherapy through their techniques contributes to the treatment of localized fat, helping to sculpt the body and reduce cellulite, less invasive and well tolerated by patients safely. However, it is noteworthy that there is a need to conduct randomized controlled trials, with larger sample size, since most of the included studies it is prospective clinical trial uncontrolled and retrospective studies.

REFERENCES

1. Venkataram J. Tumescer Liposuction: a Review. *J Cutan Aesthet Surg.* 2008;1(2):49-57.
2. Guirro ECO, Guirro RRJ. Fibro Edema Gelóide. In: Guirro ECO, Guirro RRJ *Fisioterapia dermatofuncional.* 3.ed. revisada e ampliada Barueri/SP Manole; 2004. p.347-89.
3. Koblenzer CS. Psychosocial aspects of beauty: how and why to look good. *Clin Dermatol.* 2003;21(6):473-5.
4. Ferraro GA, De Francesco F, Cataldo C, Rossano F, Nicoletti G, D'Anfrea F. Synergistic effects of cryolipolysis and shock waves for noninvasive body contouring. *Aesthetic Plast Surg.* 2012;36(3):666-79.
5. Meyer PF. Desenvolvimento e aplicação de um protocolo de avaliação fisioterapêutica em pacientes com fibro edema gelóide. *Fisioterapia em Movimento.* 2004;18(1):75-83.
6. Meyer PF, Cavalcante JL, Medeiros ML, Dantas JSC, Mendonça WCM, Ronzio OA, Silva RMV. Efeitos das Ondas Sônicas de Baixa Frequência no Fibro Edema Gelóide: Estudo de Caso. *Rev Bras Terap e Saúde.* 2011;1(2):95-100.
7. Grazer FM, Jong RH. Fatal outcome from liposuction: Census survey of cosmetic surgeons. *Plast Reconstr Surg.* 2000;105(1):436-46.
8. Commons GW, Halperin B, Chang CC. Large volumes liposuction: Review of 631 consecutive cases over 12 years. *Plast Reconstr Surg.* 2001;108(6):1753-63.
9. Cao H, Long X, Zhang H, Xu L, Liu Z, Wang X. The efficacy and safety study of JCS-01 non-invasive focused ultrasound fat reduction machine. *Zhongguo Yi Liao Qi Xie Za Zhi.* 2012;36(5):370-2.
10. Adatto MA, Adatto-Neilson R, Novak P, Krotz A, Halter G. Body shaping with acoustic wave therapy AWT(®)/EPAT(®): randomized, controlled study on 14 subjects. *J Cosmet Laser Ther.* 2011;13(6):291-6.
11. Coleman KM, Coleman WP 3rd, Benchetrit A. Non-invasive, external ultrasonic lipolysis. *Semin Cutan Med Surg.* 2009;28(4):263-7.
12. Fatemi A. High-intensity focused ultrasound effectively reduces adipose tissue. *Semin Cutan Med Surg.* 2009;28(4):257-62.
13. Sasaki GH, Oberg K, Tucker B, Gaston M. The effectiveness and safety of topical PhotoActiv phosphatidylcholine-based anti-cellulite gel and LED (red and near-infrared) light on Grade II-III thigh cellulite: a randomized, double-blinded study. *J Cosmet Laser Ther.* 2007;9(2):87-96.
14. Del Pino EM, Rosado RH, Azuela A, Graciela Guzmán M, Argüelles D, Rodriguez C, Rosado GM. Effect of controlled volumetric tissue heating with radiofrequency on cellulite and the subcutaneous tissue of the buttocks and thighs. *J Drugs Dermatol.* 2006;5(8):714-22.
15. Alexiades-Armenakas M, Dover JS, Arndt KA. Unipolar radiofrequency treatment to improve the appearance of

- cellulite. *J Cosmet Laser Ther.* 2008;10(3):148-53.
16. Sadick N, Magro C. A study evaluating the safety and efficacy of the velaSmooth system in the treatment of cellulite. *J Cosmet Laser Ther.* 2007;9(1):15-20.
 17. Sadick NS, Mulholland RS. A prospective clinical study to evaluate the efficacy and safety of cellulite treatment using the combination of optical and RF energies for subcutaneous tissue heating. *J Cosmet Laser Ther.* 2004;6(4):187-90.
 18. Hamida ZH, Comtois AS, Portmann M, Boucher JP, Savard R. Effect of electrical stimulation on lipolysis of human white adipocytes. *Appl Physiol Nutr Metab.* 2011;36(2):271-5.
 19. Lach E. Reduction of subcutaneous fat and improvement in cellulite appearance by dual-wavelength, low-level laser energy combined with vacuum and massage. *J Cosmet Laser Ther.* 2008;10(4):202-9.
 20. Alexiades-Armenakas M. Laser and light-based treatment of cellulite. *J Drugs Dermatol.* 2007;6(1):83-4.
 21. Chang P, Wiseman J, Jacoby T, Salisbury AV, Ersek RA. Noninvasive mechanical body contouring: (Endermologie) a one-year clinical outcome study update. *Aesthetic Plast Surg.* 1998;22(2):145-53.
 22. Ersek RA, Mann GE 2nd, Salisbury S, Salisbury AV. Noninvasive mechanical body contouring: a preliminary clinical outcome study. *Aesthetic Plast Surg.* 1997;21(2):61-7.
 23. Saedi N, Kaminer M. New waves for fat reduction: High-intensity focused ultrasound. *Semin Cutan Med Surg.* 2013;32(1):26-30.
 24. Seidenari S, Bassoli S, Flori ML, Rigano L, Sparavigna A, Vesnaver R, Berardesca E. Methods for the assessment of the efficacy of products and slimming treatments for cellulite according to the Italian Interdisciplinary Group for the standardization of efficacy tests on cosmetic products. *G Ital Dermatol Venereol.* 2013;148(2):217-23.
 25. Wassef C, Rao BK. The science of cellulite treatment and its long-term effectiveness. *J Cosmet Laser Ther.* 2012;14(2):50-8.
 26. Khan MH, Victor F, Rao B, Sadick NS. Treatment of cellulite: Part II. Advances and controversies. *J Am Acad Dermatol.* 2010;62(3):373-84.
 27. Gingrass MK, Kenkel JM. Comparing ultrasound-assisted lipoplasty with suction-assisted lipoplasty. *Clin Plast Surg.* 1999;26(2):283-8.
 28. Jewell ML, Solish NJ, Desilets CS. Noninvasive body sculpting technologies with an emphasis on high-intensity focused ultrasound. *Aesthetic Plast Surg.* 2011;35(5):901-12.
 29. Peterson JD, Goldman MP. Laser, light, and energy devices for cellulite and lipodystrophy. *Clin Plast Surg.* 2011;38(3):463-74.
 30. Romanenko IM. A comparative evaluation of amphotericin pharmacokinetics in the skin and subcutaneous fatty tissue when used dermally and by phonophoresis. *Farmakol Toksikol.* 1991;54(5):50-1.
 31. Gold MH. Cellulite – an overview of non-invasive therapy with energy-based systems. *J Dtsch Dermatol Ges.* 2012;10(8):553-8.
 32. Paul M, Mulholland RS. A new approach for adipose tissue treatment and body contouring using radiofrequency-assisted liposuction. *Aesthetic Plast Surg.* 2009;33(5):687-94.
 33. DiBernardo BE. Treatment of cellulite using a 1440-nm pulsed laser with one-year follow-up. *Aesthet Surg J.* 2011;31(3):328-41.
 34. Knobloch K, Joest B, Vogt PM. Cellulite and extracorporeal Shockwave therapy (CelluShock-2009) - a randomized Trial. *Women's Health.* 2010;10:29.
 35. Dierickx CC, Mazer JM, Sand M, Koenig S, Arigon V. Safety, tolerancy and patient satisfaction with noninvasive cryolipolysis. *Dermatol Surg.* 2013;39(8):1209-16.
 36. Mlosek RK, Wozniak W, Malinowska S, Lewandowski M, Nowicki A. The effectiveness of anticellulite treatment using tripolar radiofrequency monitored by classic and high-frequency ultrasound. *J Eur Acad Dermatol Venereol.* 2012;26(6):696-703.
 37. Mlosek RN, Debowska RM, Lewandowski M, Malinowska S, Nowicki A, Eris I. Imaging of the skin and subcutaneous tissue using classical and high-frequency ultrasonographies in anti-cellulite therapy. *Skin Res Technol.* 2011;17(4):461-8.
 38. Jewell ML, Baxter RA, Cox SE, Donofrio LM, Dover JS, Glogau RG, Kane MA, Weiss RA, Martin P, Schlessinger J. Randomized sham-controlled trial to evaluate the safety and effectiveness of a high-intensity focused ultrasound device for noninvasive body sculpting. *Plast Reconstr Surg.* 2011;128(1):253-62.
 39. Fatemi A, Kane MA. High-intensity focused ultrasound effectively reduces waist circumference by ablating adipose tissue from the abdomen and flanks: a retrospective case series. *Aesthetic Plast Surg.* 2010;34(5):577-82.
 40. Trelles MA, Van der Lugt C, Mordon S, Ribé A, Al-Zarouni M. Histological findings in adipocytes when cellulite is treated with a variable-emission radiofrequency system. *Lasers Med Sci.* 2010;25(2):191-5.

41. Bayrakci Tunay V, Akbayrak T, Bakar Y, Kayihan H, Ergun N. Effects os mechanical massage, manual lymphatic drainage and connective tissue manipulation techniques on fat mass in women with cellulite. *J Eur Acad Dermatol Venereol*. 2010;24(2):138-42.
42. Brightman L, Weiss L, Chappas AM, Karen J, Hale E, Bernstein L, Geronemus RG. Improvement in arm and post-partum abdominal and flank subcutaneous fat deposits and skin laxity using bipolar radiofrequency, infrared, vacuum and mechanical massage device. *Lasers Surg Med*. 2009;41(10):791-8.
43. Christ C, Brenke R, Sattler G, Siems W, Novak P, Daser A. Improvement in skin elasticity in the treatment os cellulite and connective tissue weakness by means of extracorporeal pulse activation therapy. *Aesthet Surg J*. 2008;28(5):538-44.
44. Moreno-Moraga J, Valero-Altés T, Riquelme AM, Isarria-Marcosy MI, De La Torres JR. Body contouring by non-invasive transdermal focused ultrasound. *Lasers Surg Med*. 2007;39(4):315-23.
45. Lugt C, Romero C, Ancona D et al. A multicenter study of cellulite treatment with a variable emission radio frequency system. *Dermatol Ther*. 2009;22:74-84.
46. Alster S, Tanzi M. Cellulite treatment using a novel combination radiofrequency, infrared light and mechanical tissue manipulation device. *J Cosmet Laser Ther*. 2005;7:81-5.
47. Sadick NS, Mullholland RS. A prospective clinical study to evaluate the efficacy and safety of cellulite treatment using the combination of optical and RF energies for subcutaneous tissue heating. *J Cosmet Laser Ther*. 2004;6:187-90.
48. Sadick N. Tissue tightening technologies: Fact or fiction. *Aesthet Surg J* 2008;28(2):180-8.
49. Manuskiatti W, Wachirakaphan C, Lektrakul N, Varothai S. Circumference reduction and cellulite treatment with a TriPollar radiofrequency device: a pilot study. *J Eur Acad Dermatol Venereol*. 2009;23:820-7.
50. Elsaie ML. Cutaneous remodeling and photorejuvenation using radiofrequency devices. *Indian J Dermatol*. 2009;54:201-5.
51. Carvalho CRF. Cosmetologia. In: Borges FS. *Modalidades Terapêuticas nas Disfunções Estéticas*. 2ª ed. São Paulo, Phorte Editora; 2010. p. 291-314.
52. Collis N, Elliot LA, Sharpe C, Sharpe D. Cellulite treatment: a myth or reality: a prospective randomized, controlled trial of two therapies, endermologie and aminophylline cream. *Plast Reconstr Surg*. 1999;104(4):1110-4.
53. Siems W, Brenke R, Sattler S, Christ C, Novak P, Daser A. Improvement in skin elasticity and dermal revitalization in the treatment of cellulite and connective tissue weakness by means of Extracorporeal Pulse Activation Therapy: EPAT. *Aesthet Surg J*. 2008;28:538-44.
54. Yip HK, Chang LT, Sun CK, Youssef AA, Sheu JJ, Wang CJ. Shock wave therapy applied to rat bone marrow-derived mononuclear cells enhances formation of cells stained positive for CD31 and vascular endothelial growth factor. *Circ J*. 2008;72:150-6.
55. Mittermayr R, Hartinger J, Antonic V, Meini A, Pfeifer S, Stojadinovic A, Schaden W, Redi H. Extracorporeal shock wave therapy (ESWT) minimizes ischemic tissue necrosis irrespective of application time and promotes tissue revascularization by stimulating angiogenesis. *Ann Surg*. 2011;253:1024-32.
56. Manstein D, Laubach H, Watanabe K, Farinelli W, Zurakowski D, Anderson RR. Selective cryolysis: a novel method of noninvasive fat removal. *Lasers Surg Med*. 2008;40:595-604.
57. Zelickson B, Egbert BM, Preciado J, Allison J, Springer K, Rhoades RW, Manstein D. Cryolipolysis for noninvasive fat cell destruction: initial results from a pig model. *Dermatol Surg*. 2009;35:1462-70.
58. Klein KB, Zelickson B, Riopelle JG, Okamoto E, Bachelor EP, Harry RS, Preciado JA. Noninvasive cryolipolysis for subcutaneous fat reduction does not affect serum lipid levels or liver function tests. *Lasers Surg Med*. 2009;41:789-90.
59. Avram MM, Harry RS. Cryolipolysis for subcutaneous fat layer reduction. *Lasers Surg Med*. 2009;41:703-8.